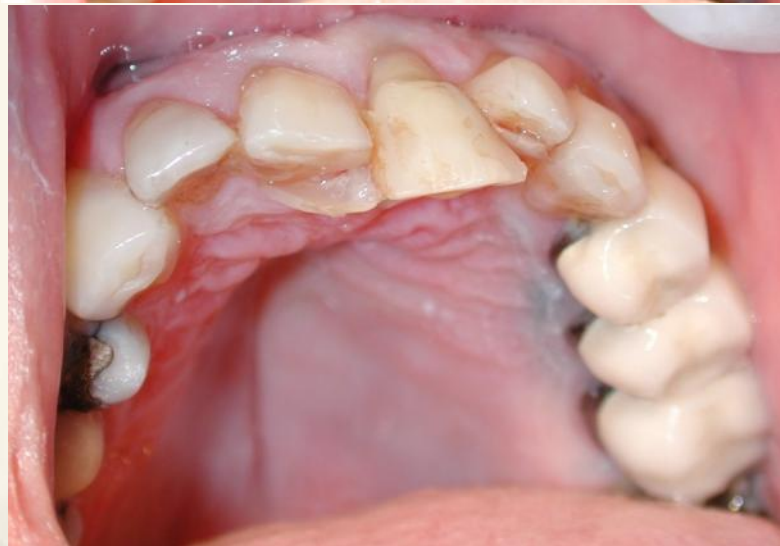
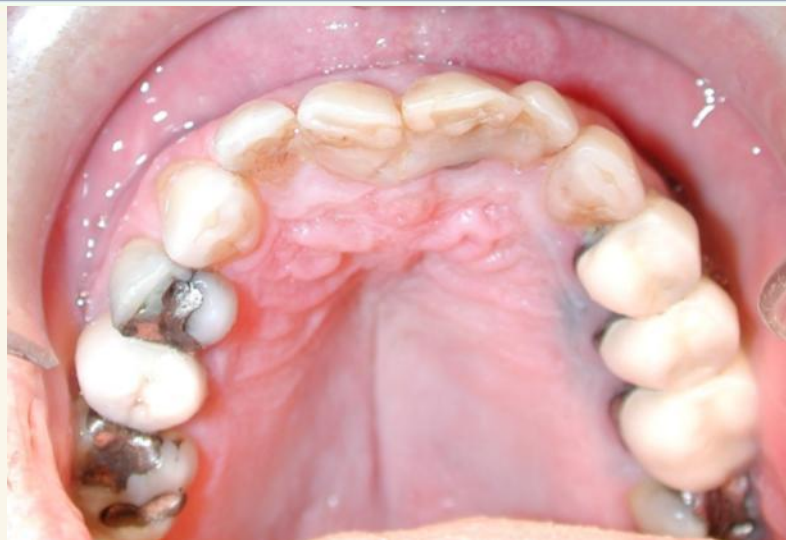
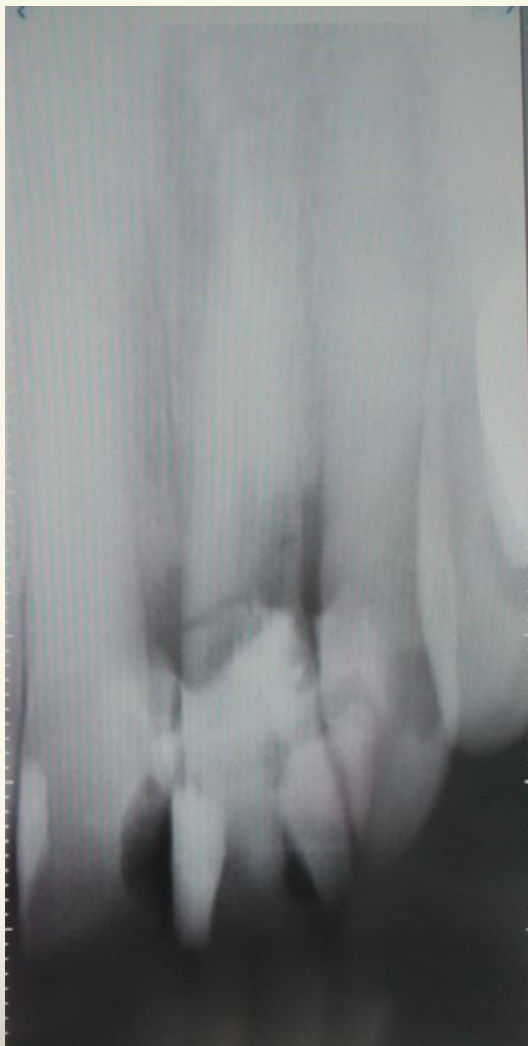The use of “Saturn” for Immediate loading after extraction & Immediate implantation

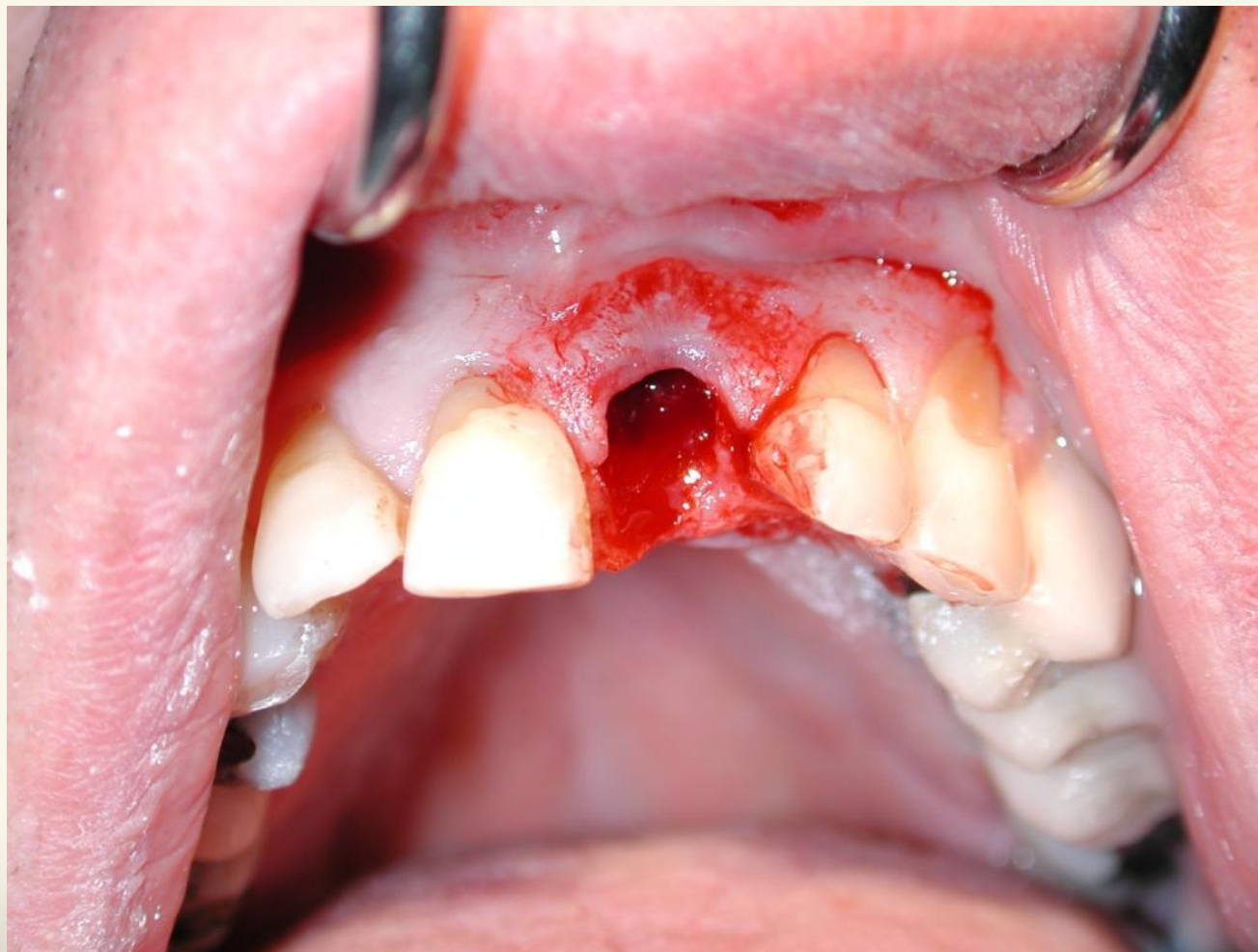Dr. Zvi Laster DMD

**HEAD OF ORAL & MAXILLOFACIAL SURGERY DEP. PORIYA HOSPITAL-TIBERIAS-
ISRAEL**

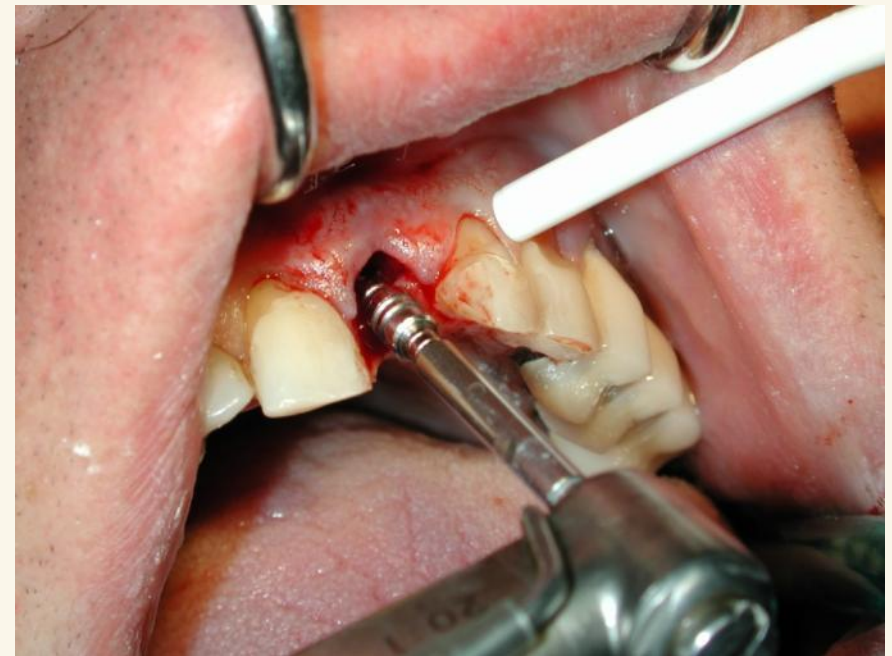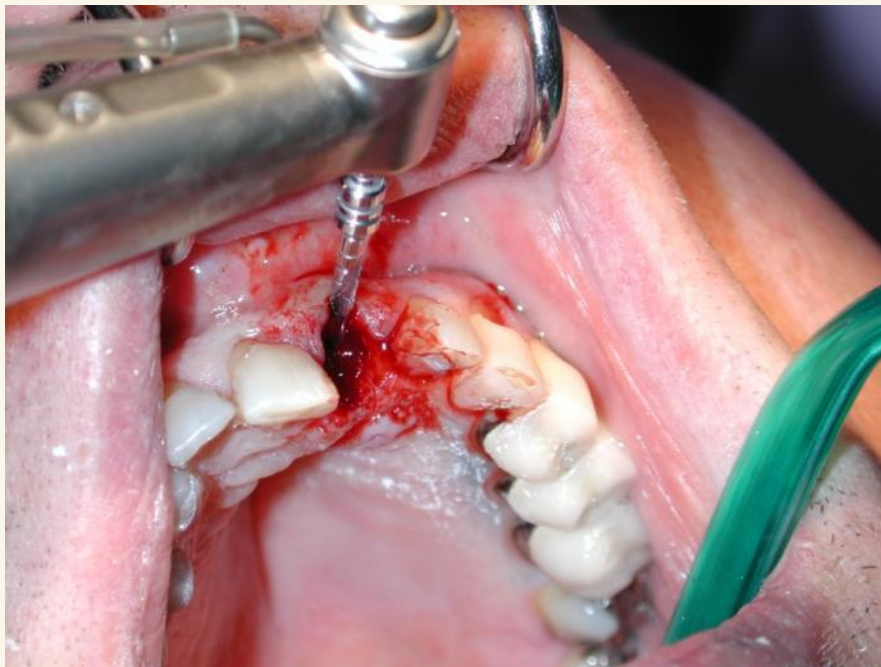
Case 1-Fractured Crown Splinted with Composite



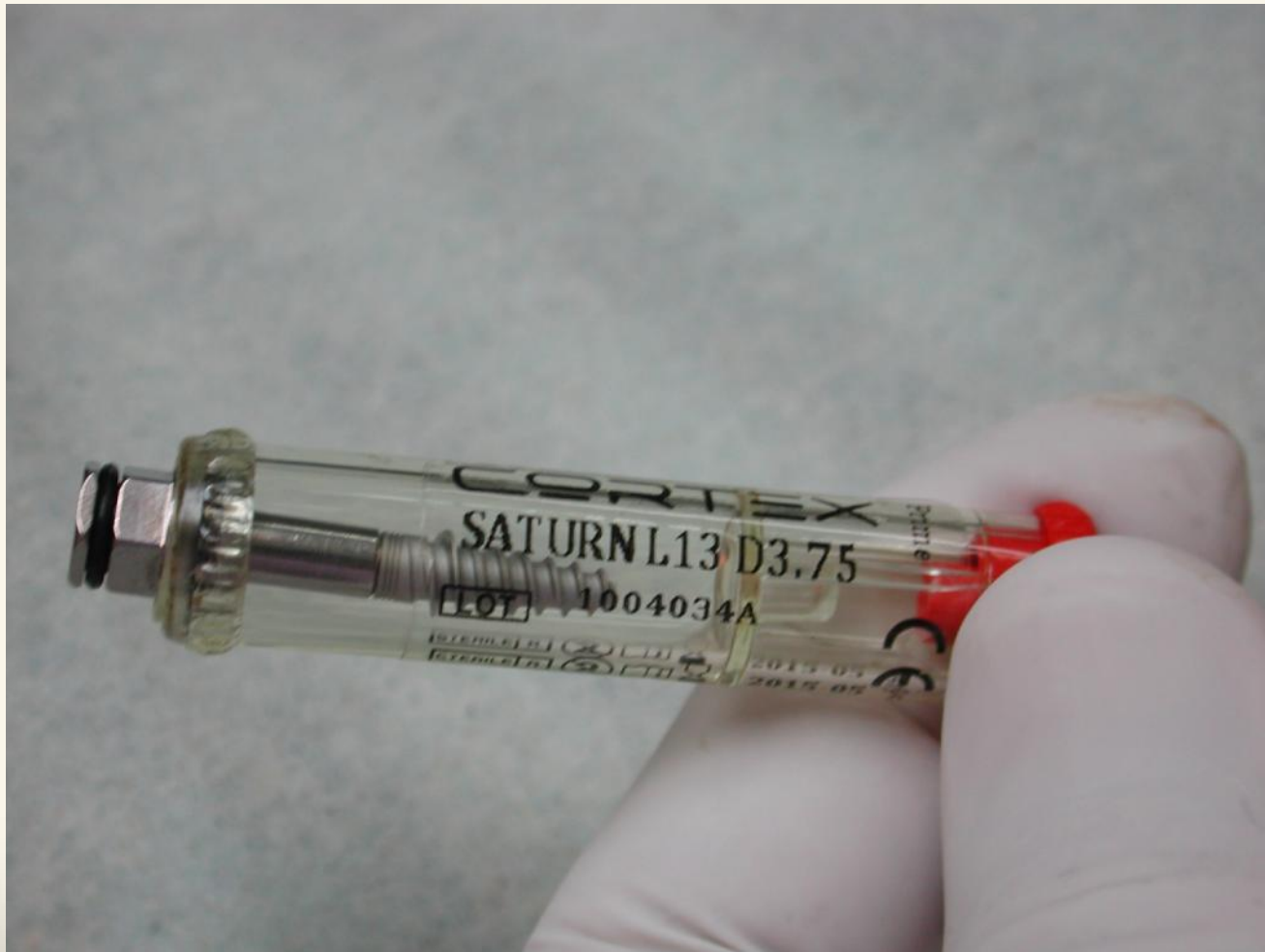
Root Extracted



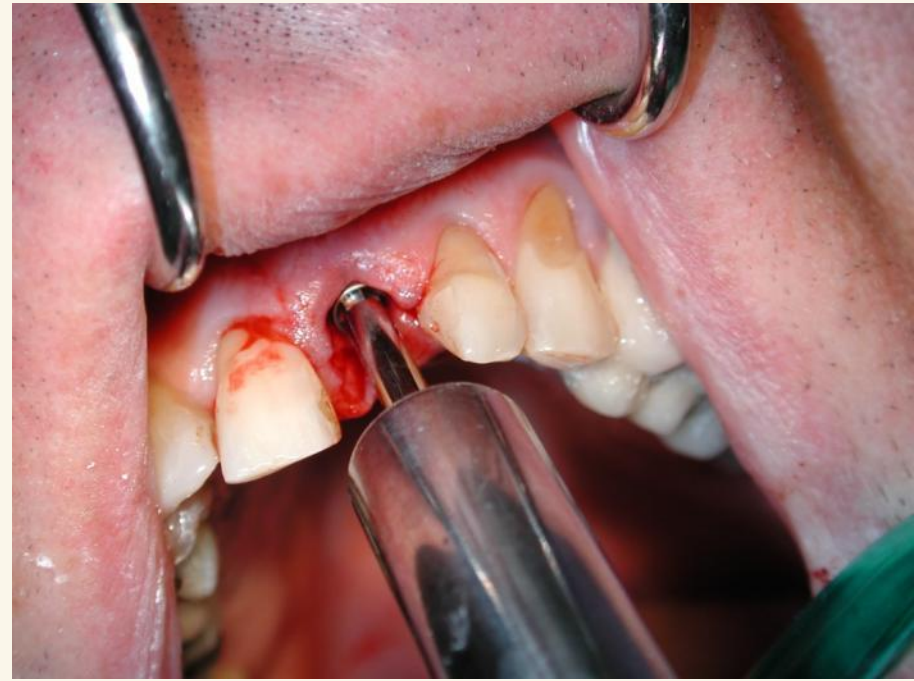Oblique Initial drilling & Then straight



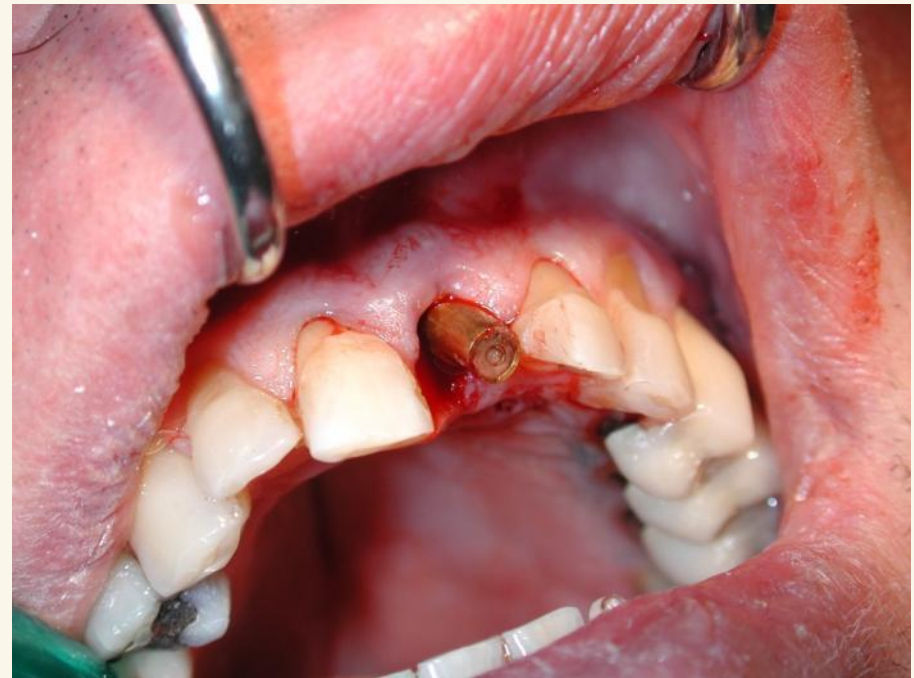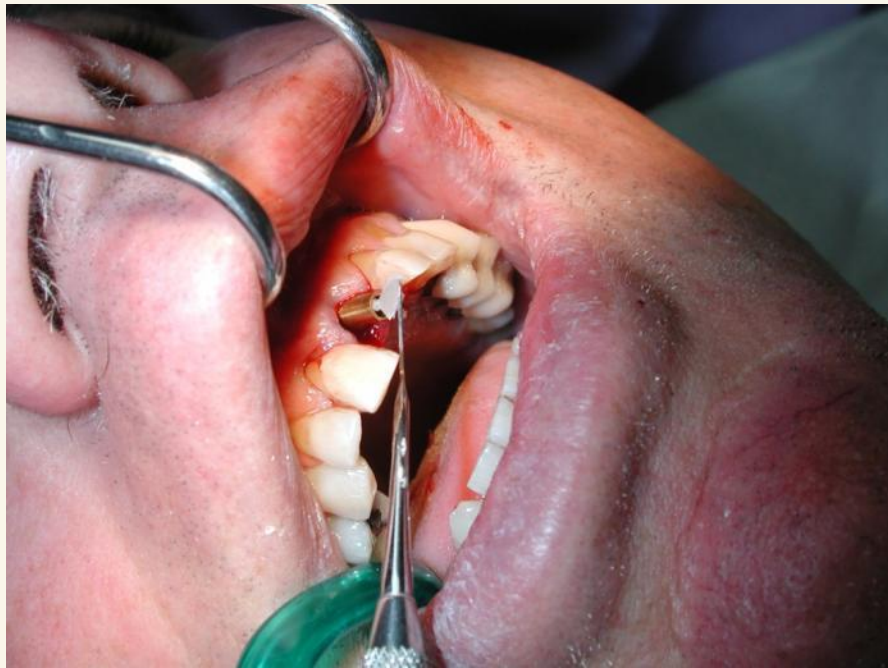“Saturn” Package



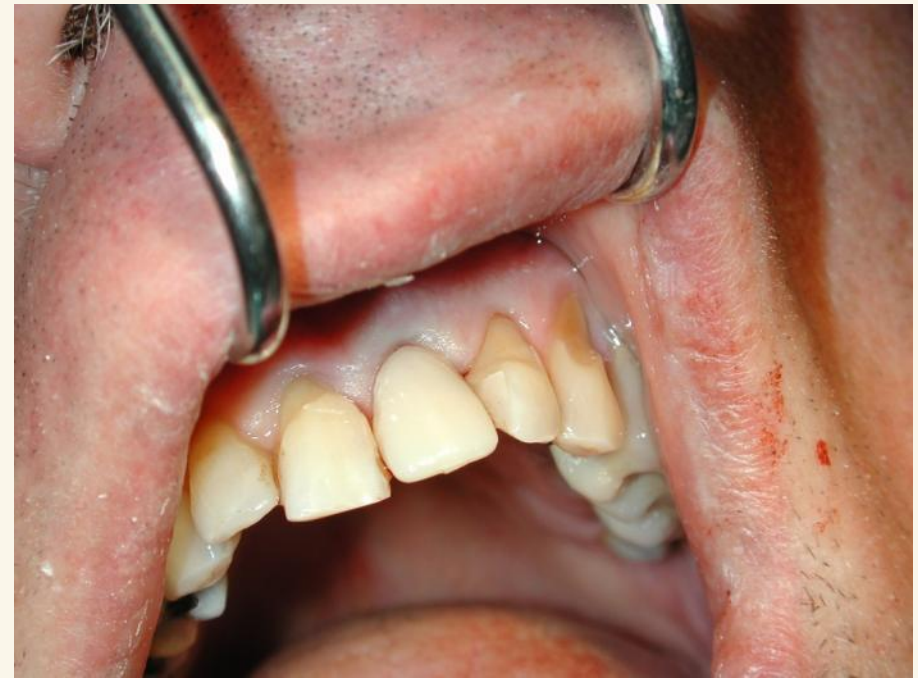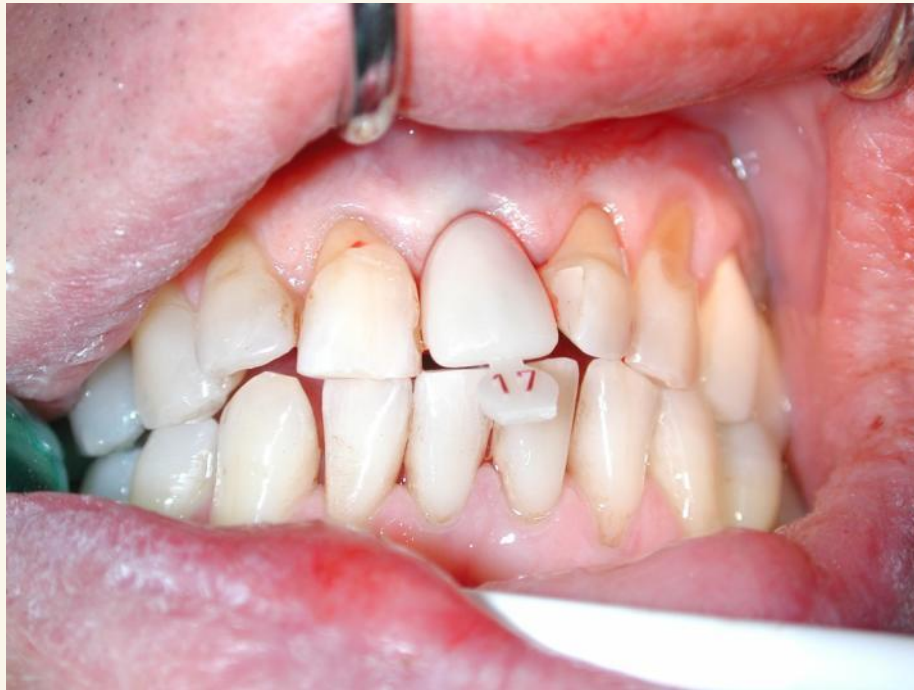Inserting the “Saturn”



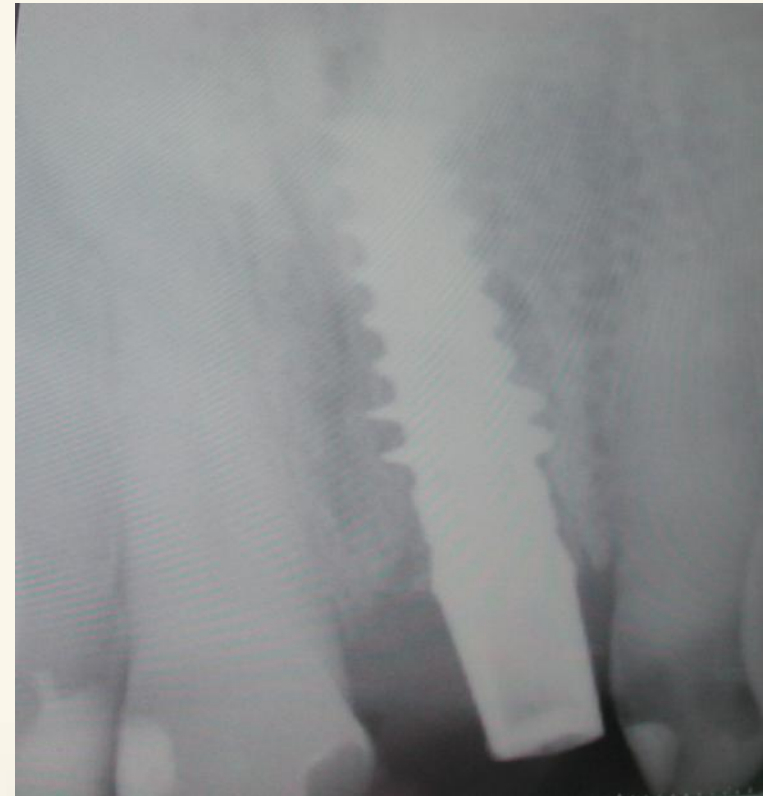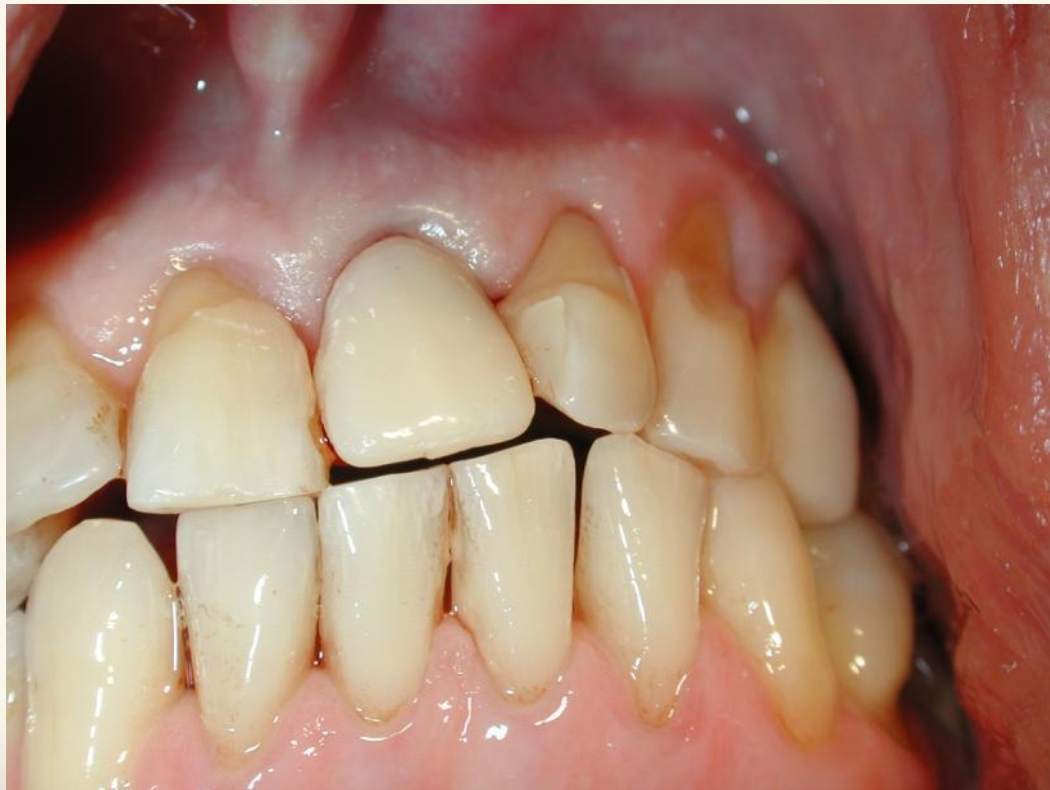Abutment sealing with Wax



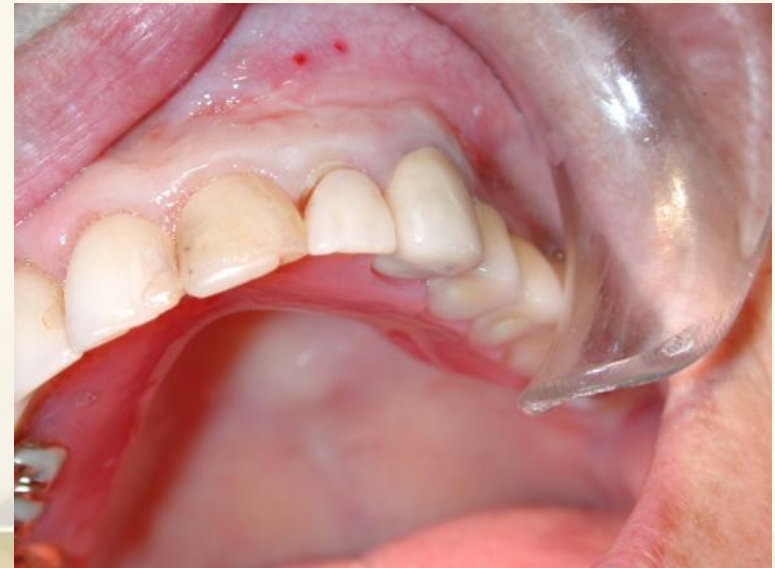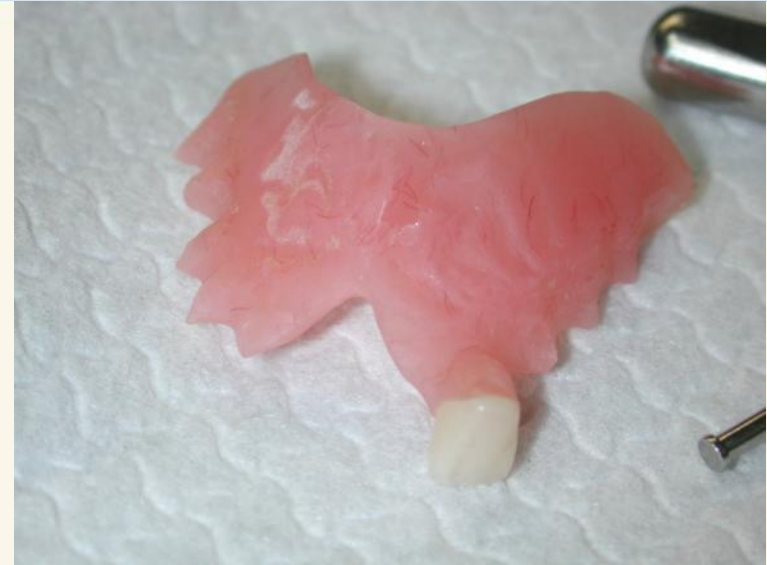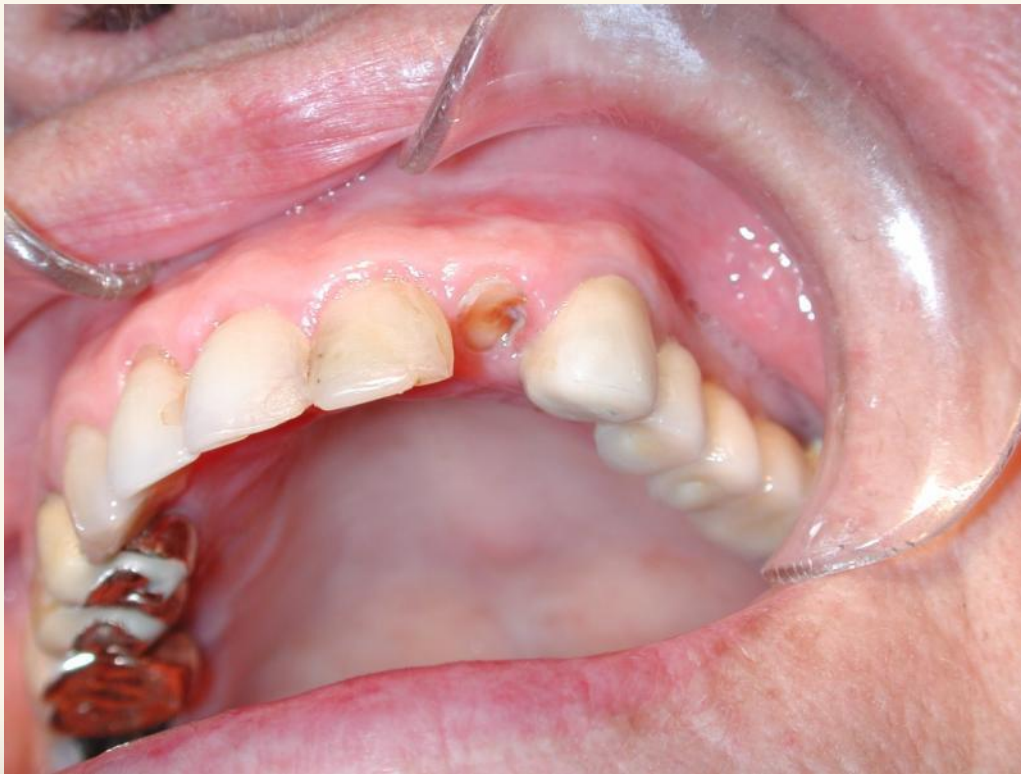Preparation of the Temporary crown



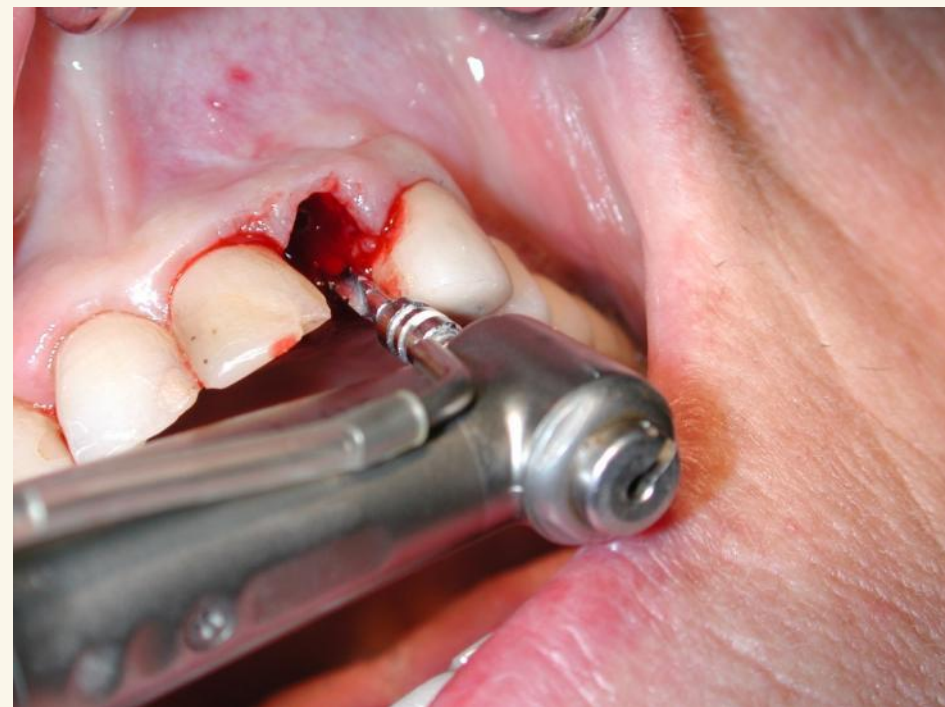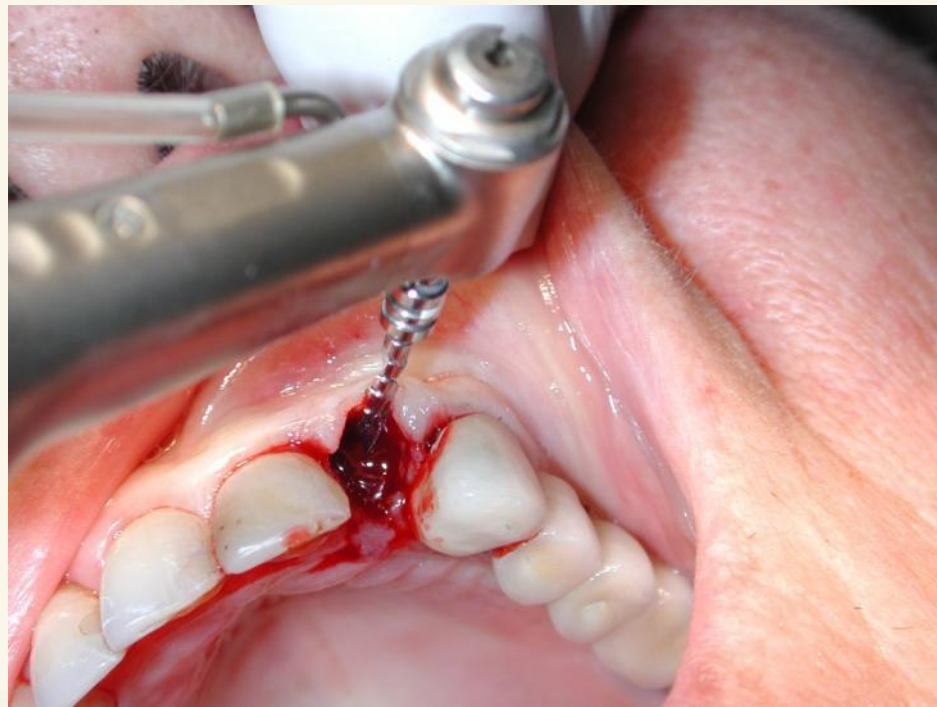Temporary Crown Without occlusal Contact



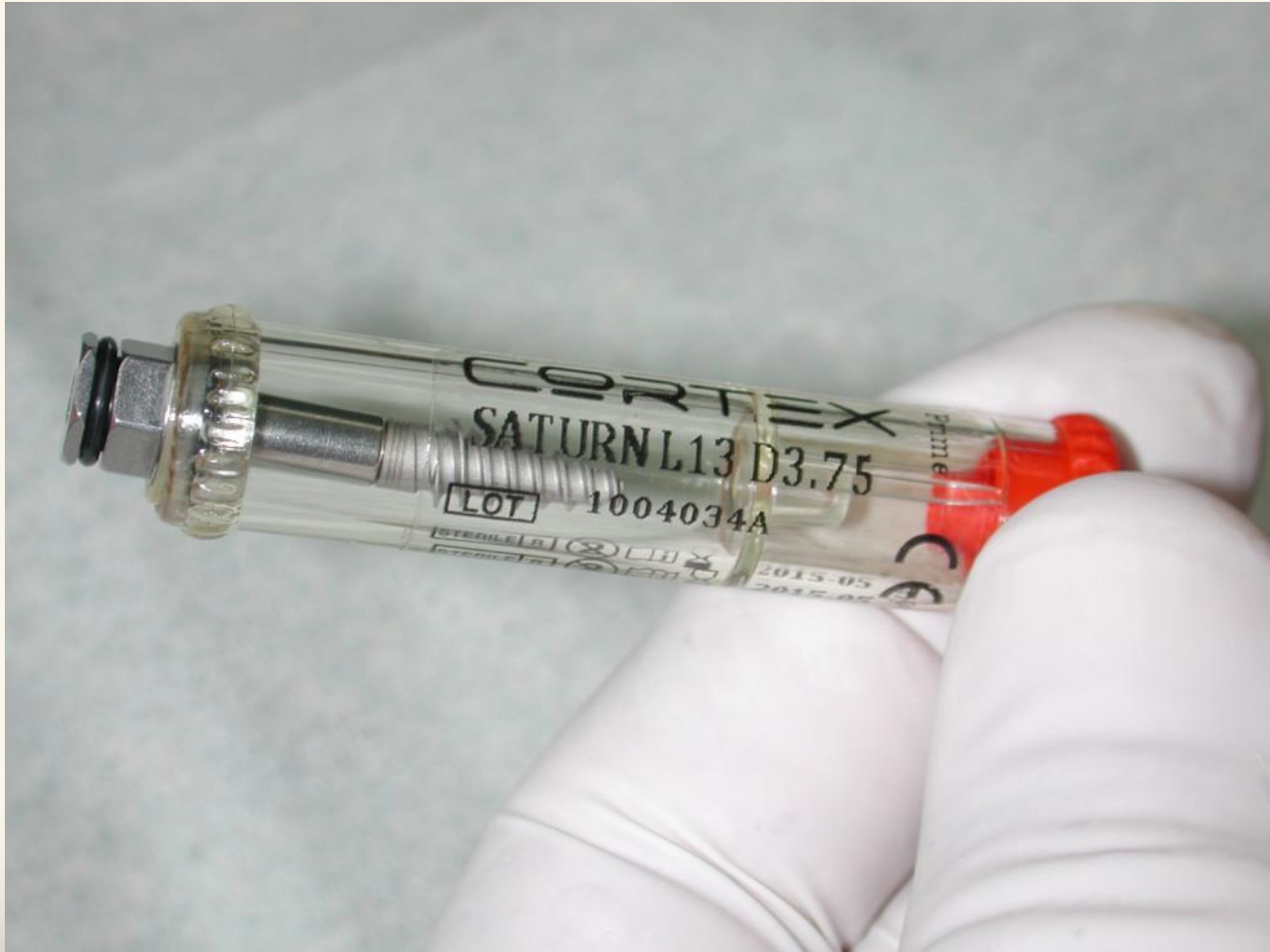Case 2 – Fractured Crown



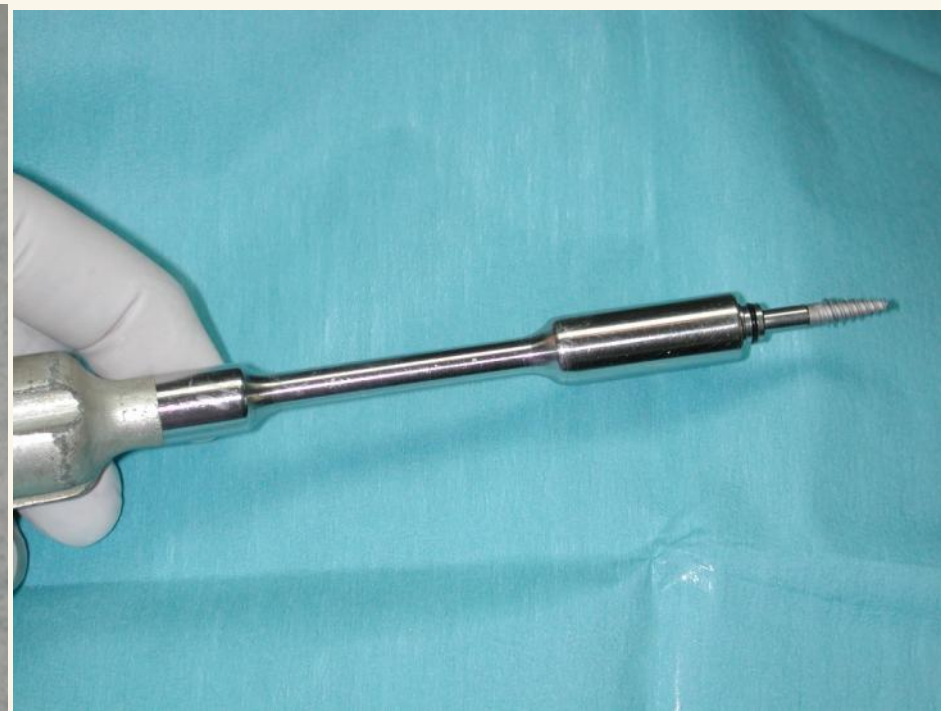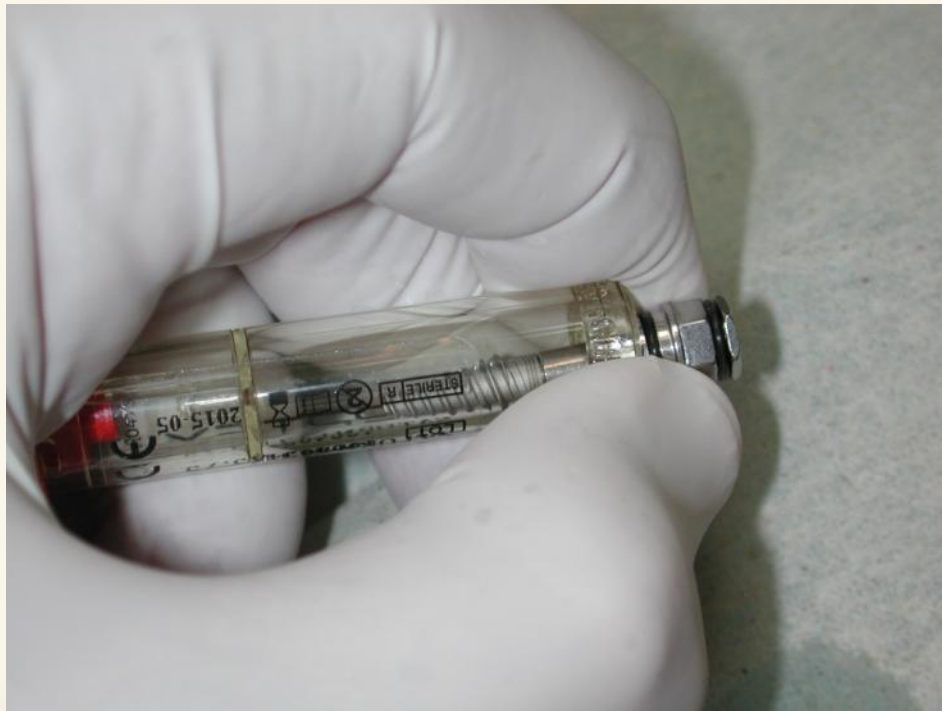Oblique Initial drilling & Then straight



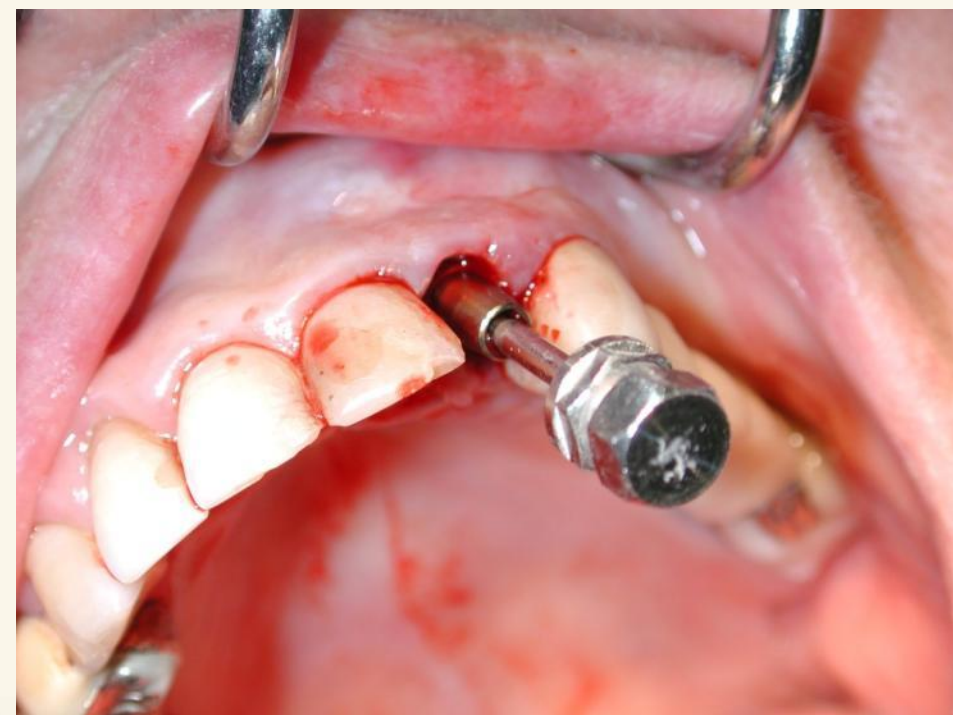
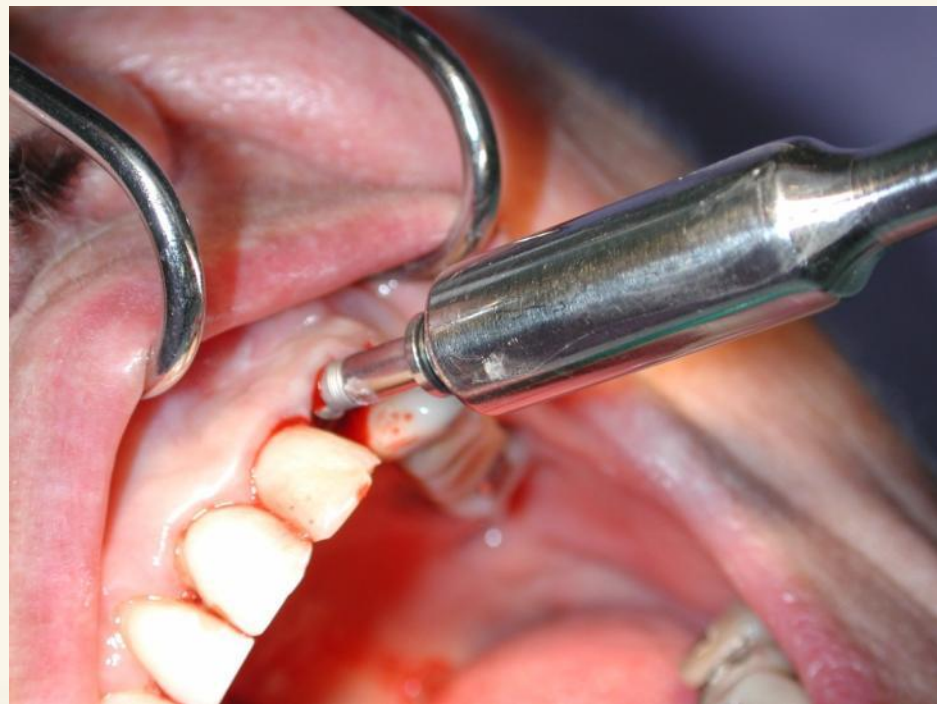“Saturn Package”



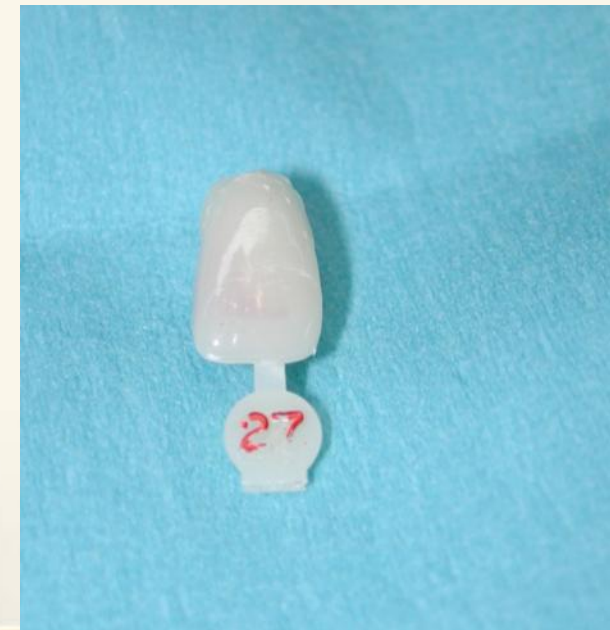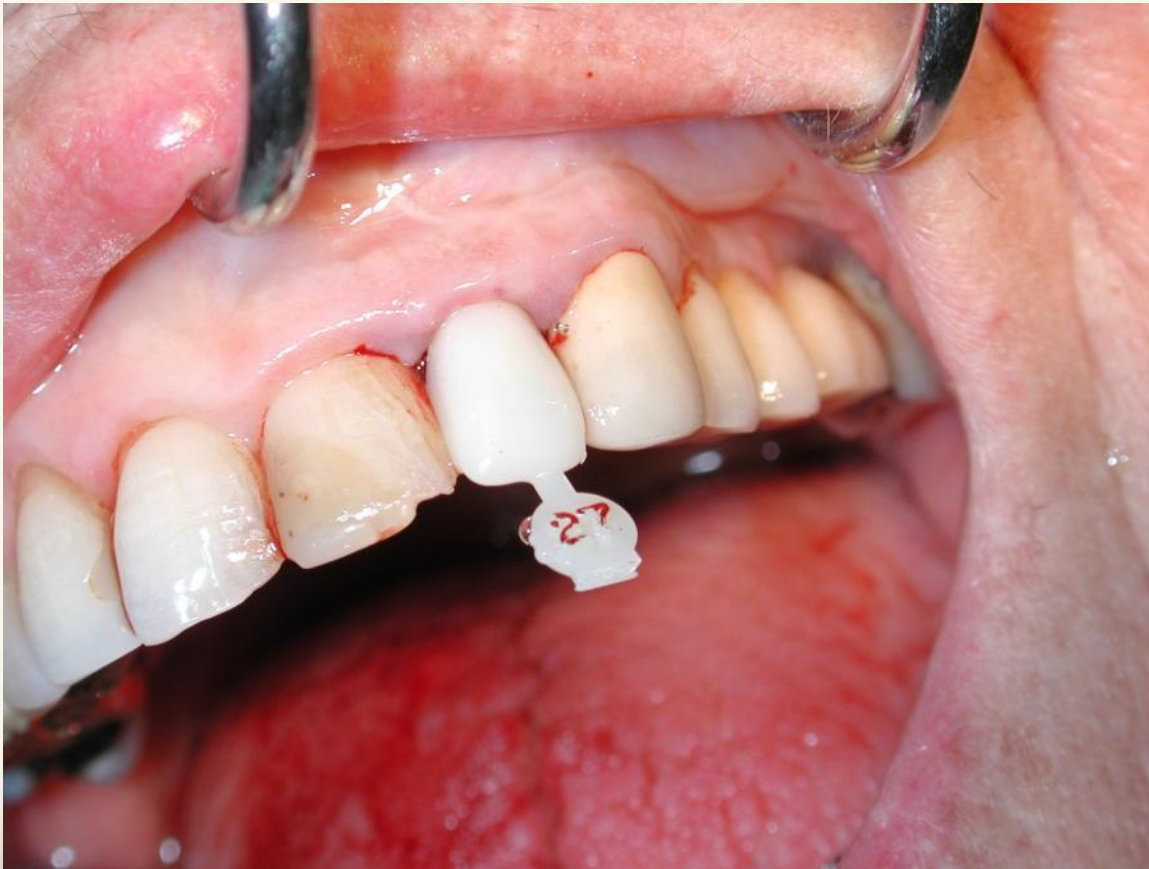Carrying the Implant with Straight Handle



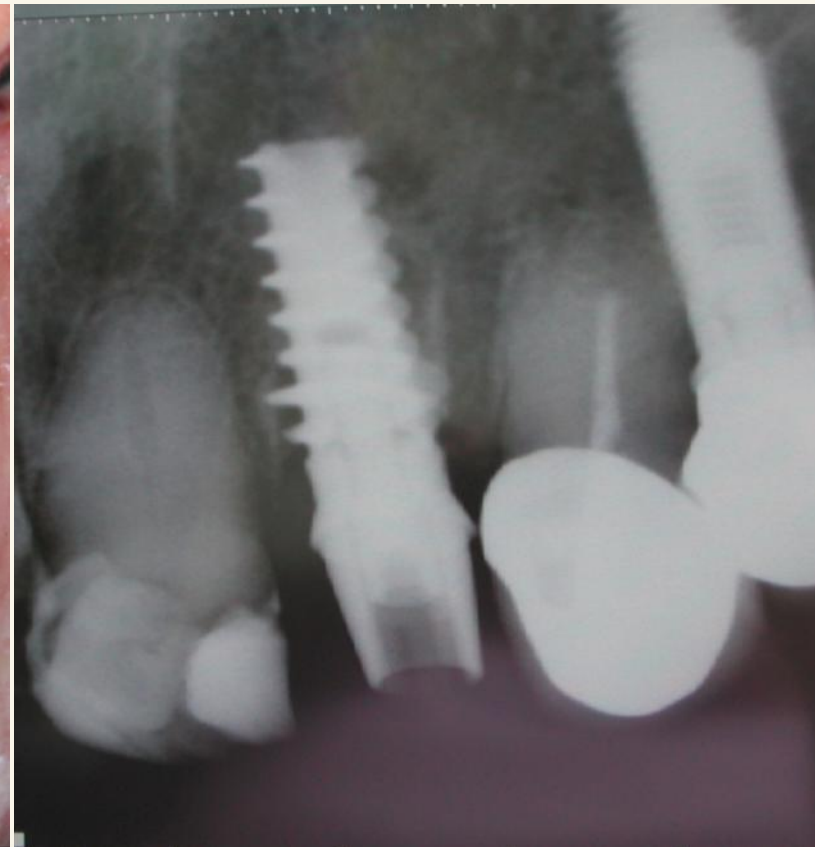
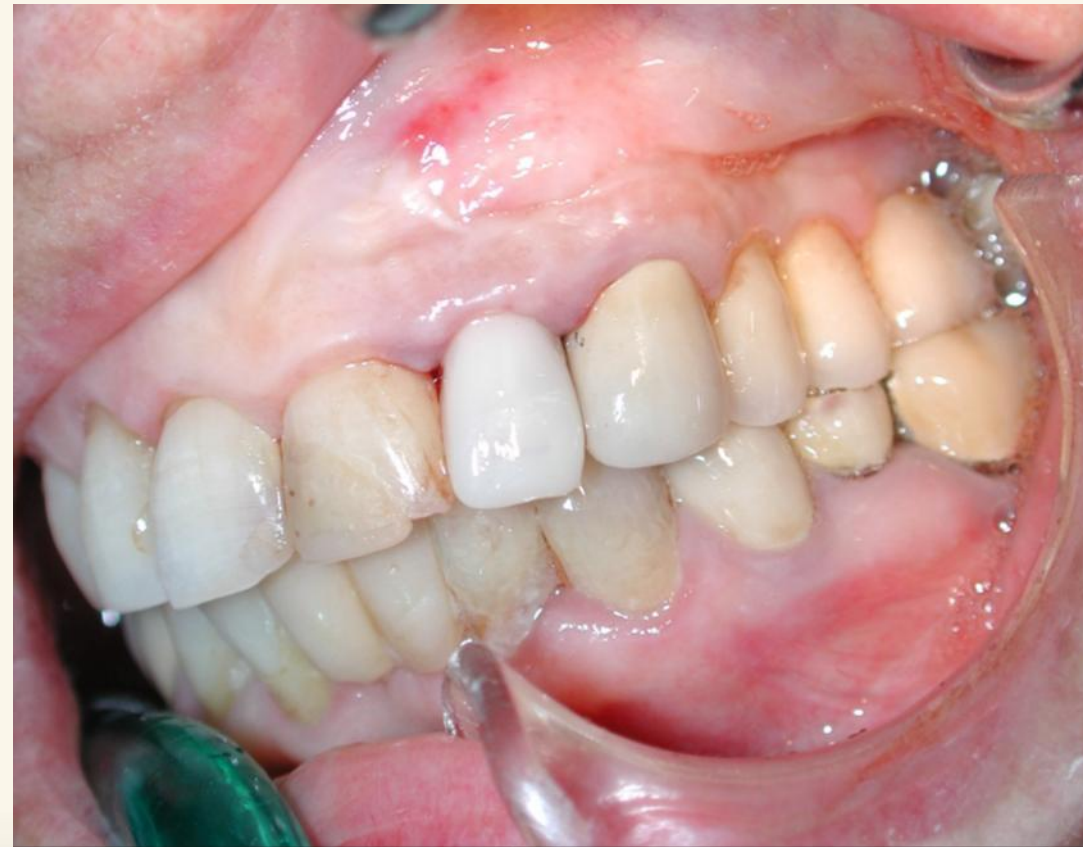Oblique Initial Insertion & Then Straight

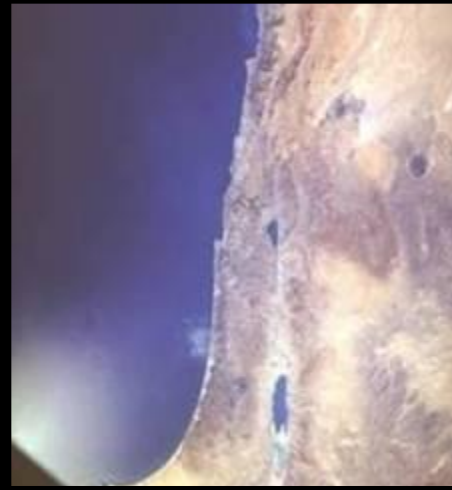
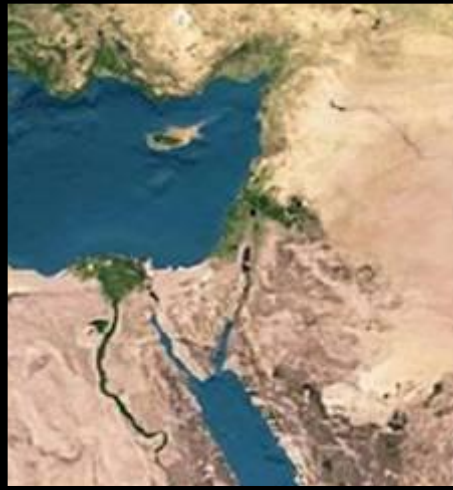
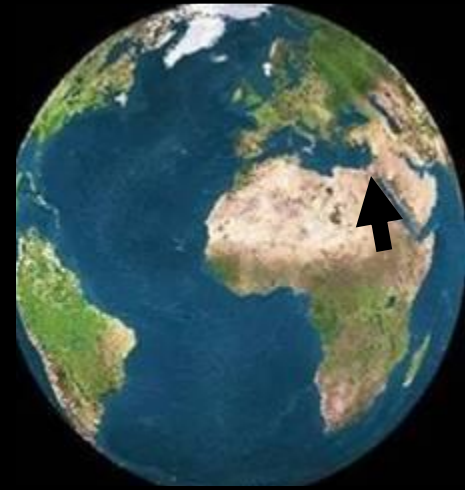Preparing the Temporary Crown



Finished Temporary Crown





Dr` Zvi Laster
Head of
Maxillofacial Surgery Dept
Tiberias
Israel

