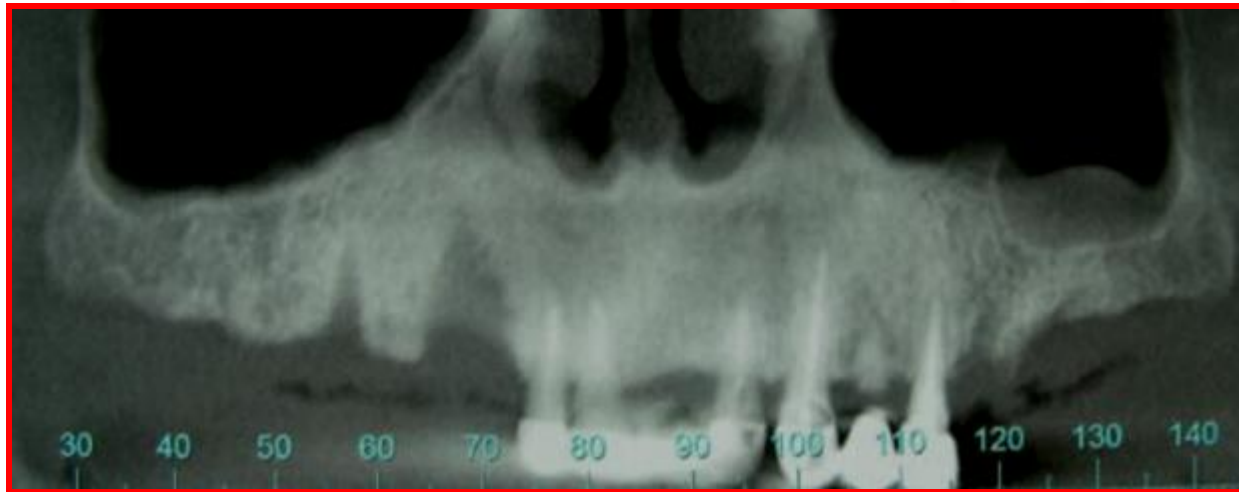
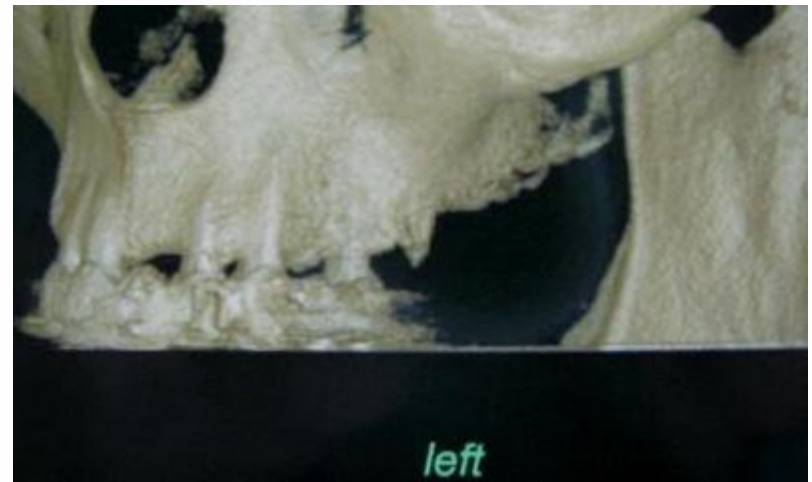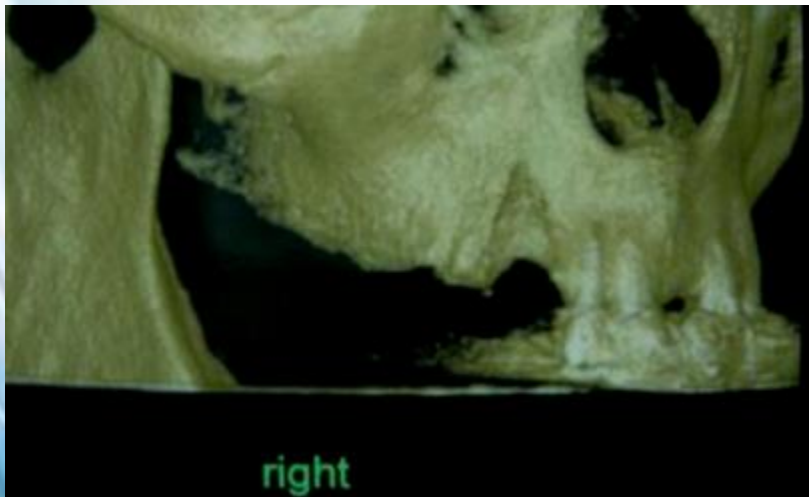
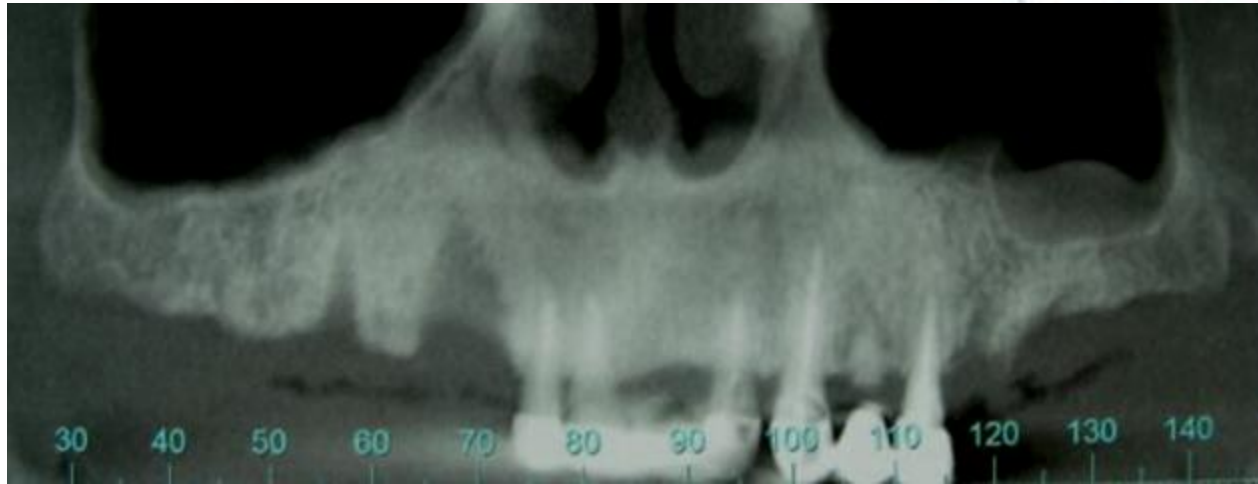


Case report of 6 Dynamic cortex implants



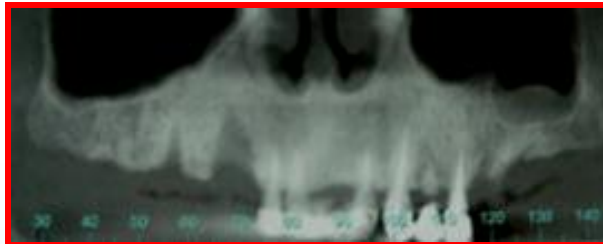
Dr. Yaacov Levy

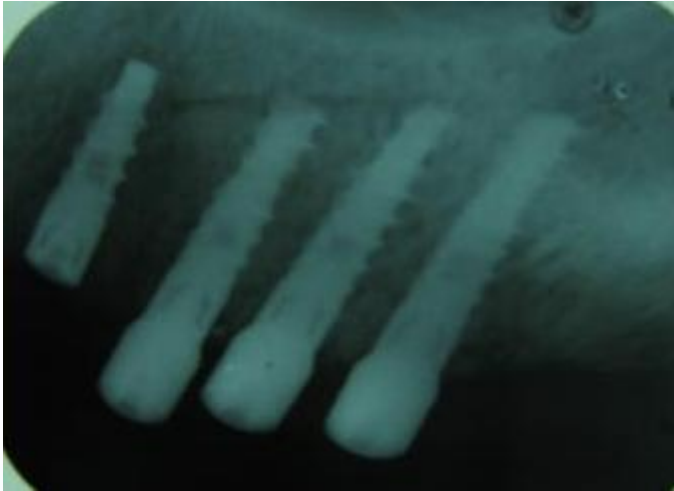


Treatment Plane

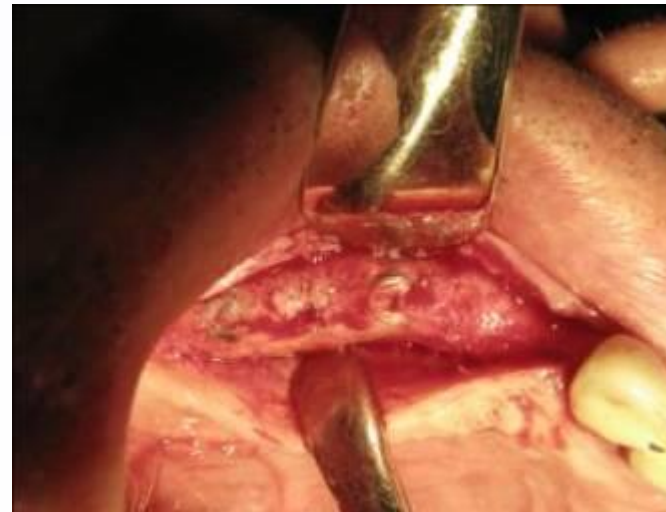
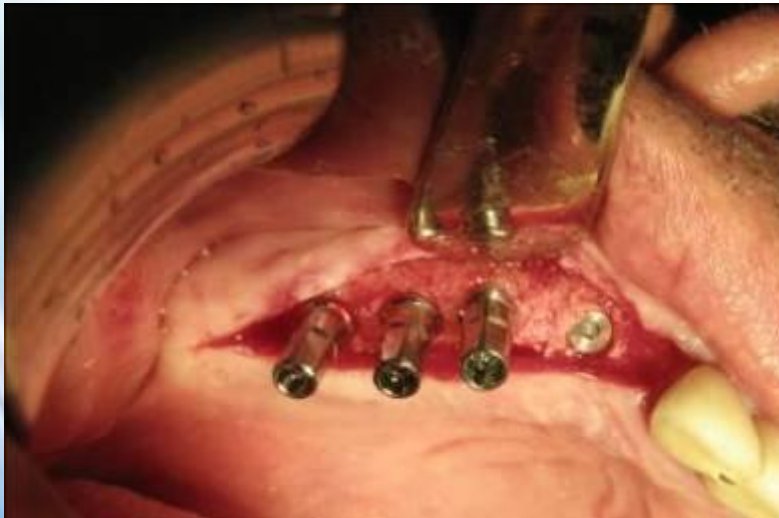
60 y. healthy male, missing teeth 14- 17
and 26-27. bony defect in 14.

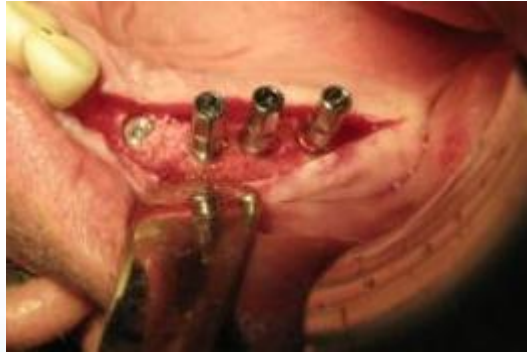- I. 3 implants in 15,16,17 and augmentation in socket of 14.
- II. Uncovering of the implants, inserting implant in 14 and placing temporary bridge 14-17 on the 3 implants.
- III. One stage two implant in 26,27.
- IV. Uncovering implant in 14 and taking impressions for final resoration



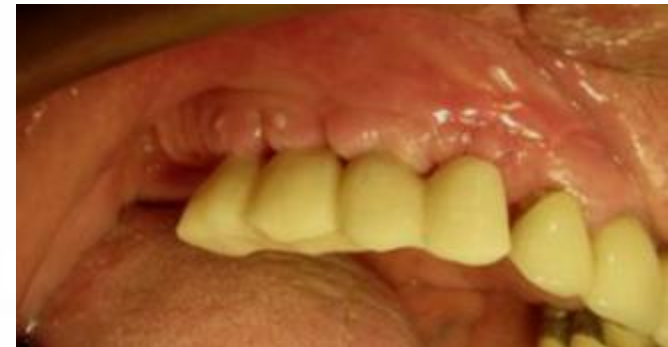
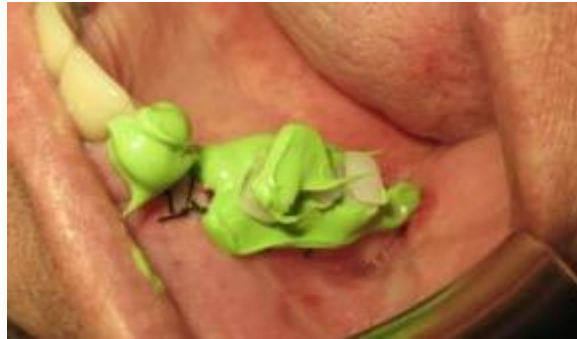
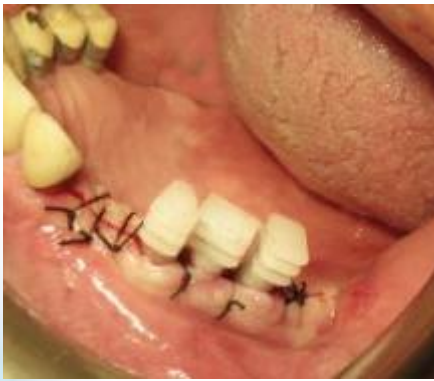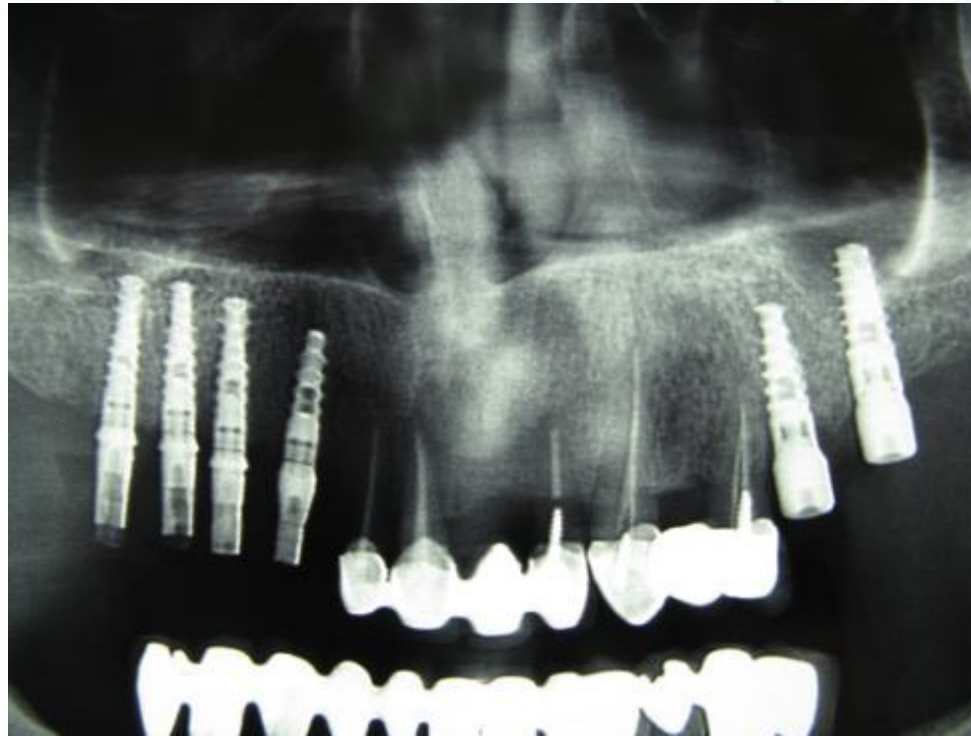**Uncovering the implants
15,16,17 and inserting
implant in 14**



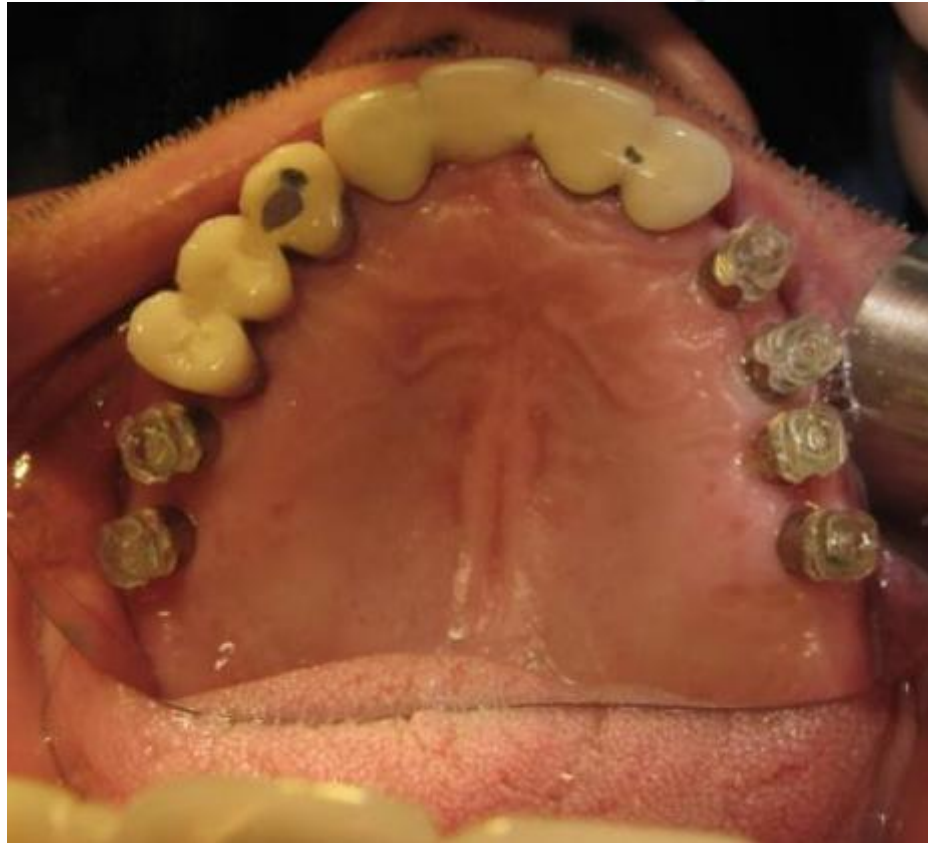

**Taking impressions for
temporary bridge 14-17**



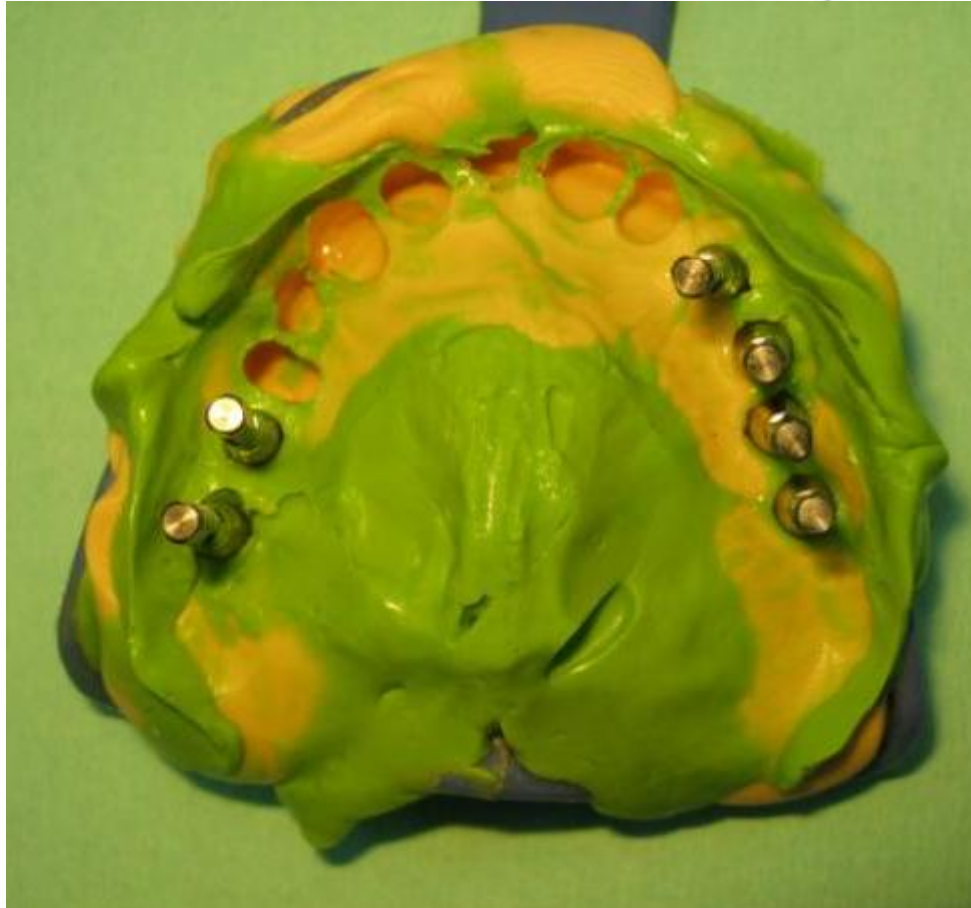

Panoramic x-ray befor taking impressions for final restoration

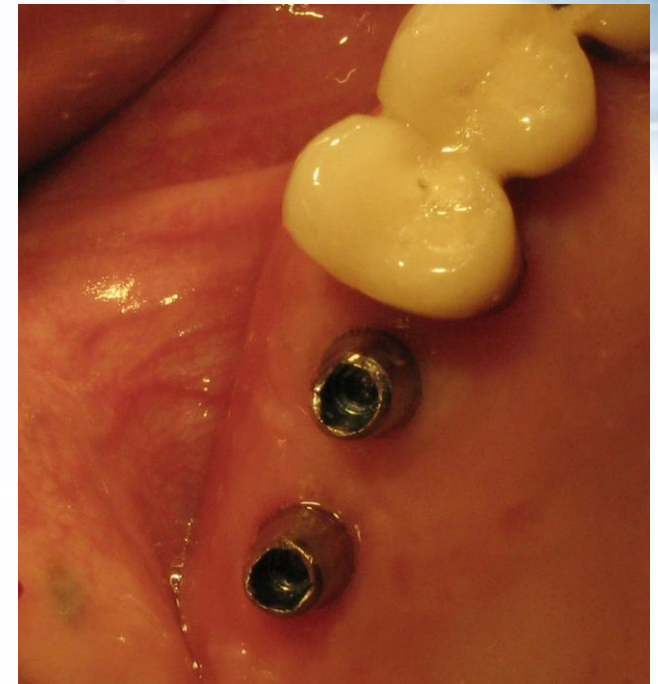
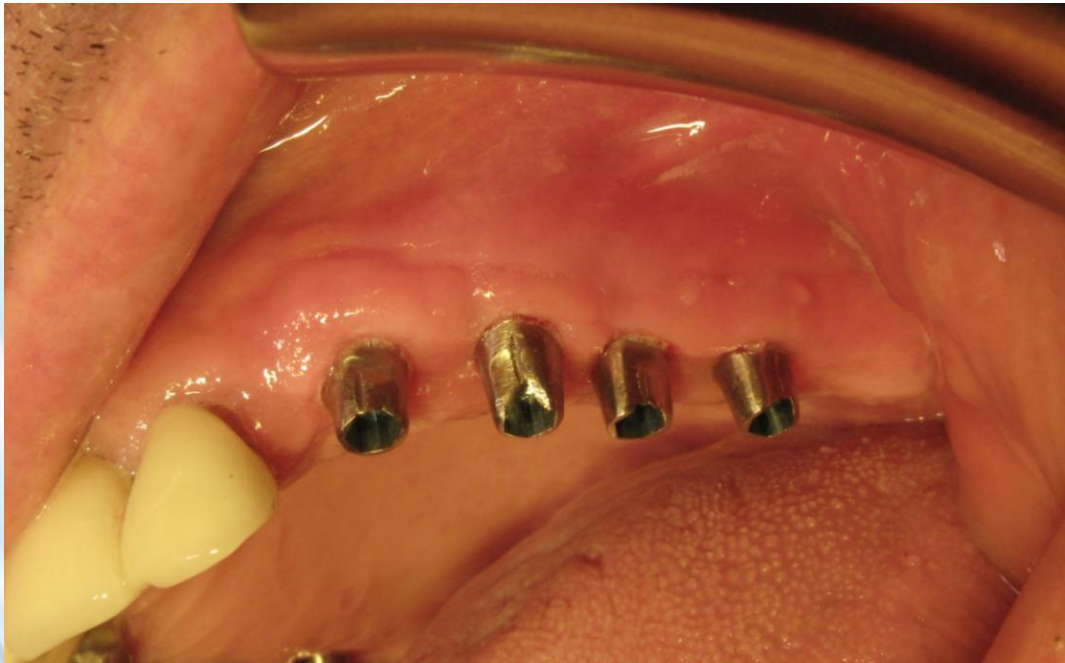
**Premium
abutment &
impression coping**

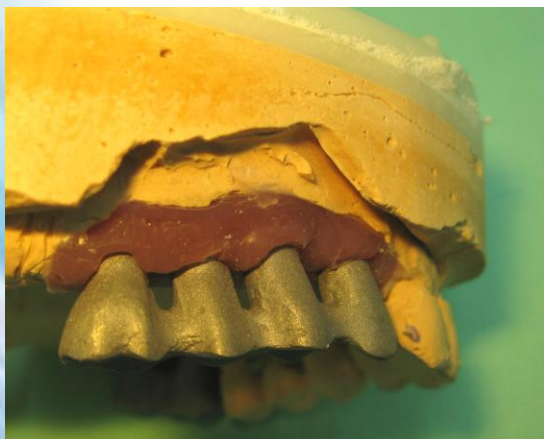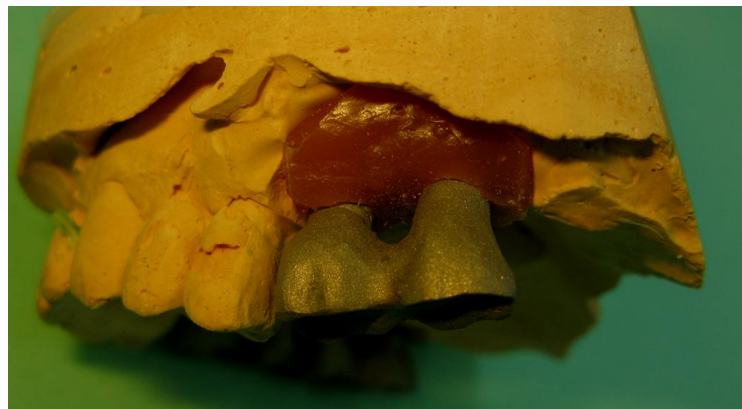
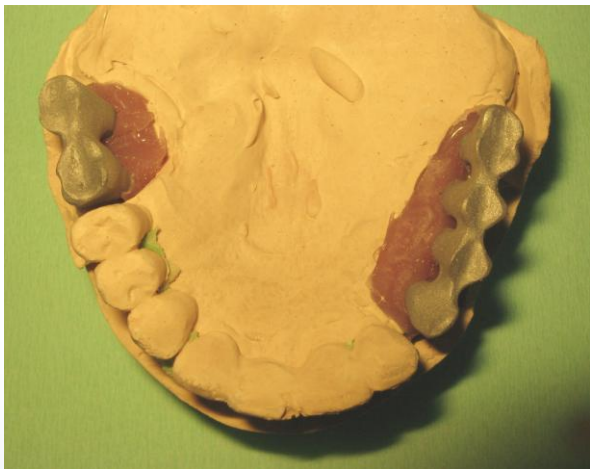
**using the plastic impression coping of
the premium package**

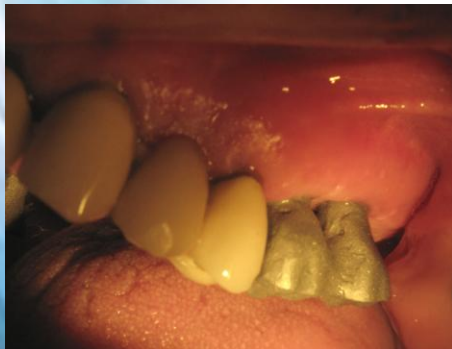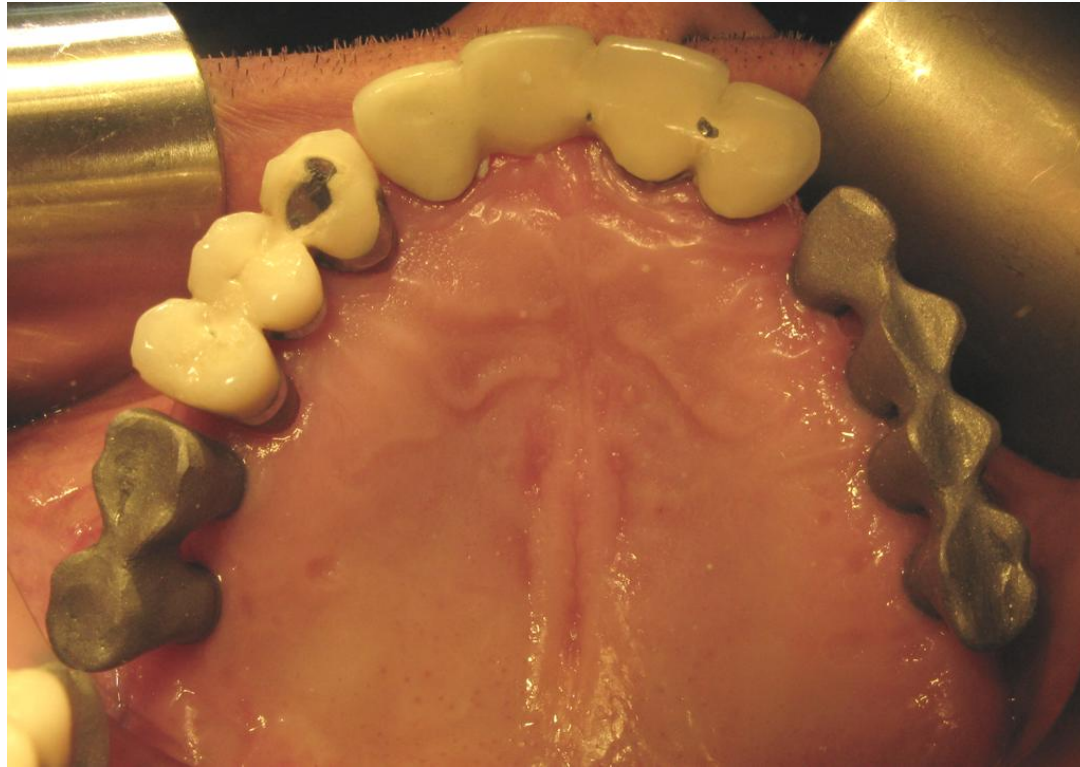


Impresion with analogs

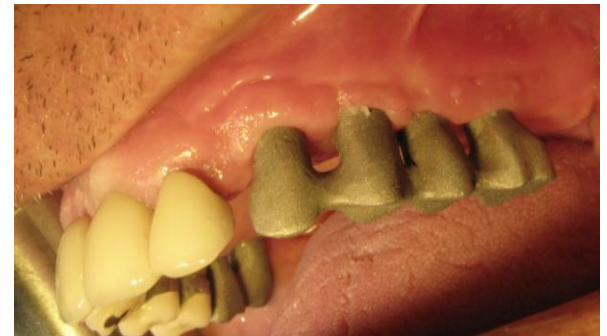

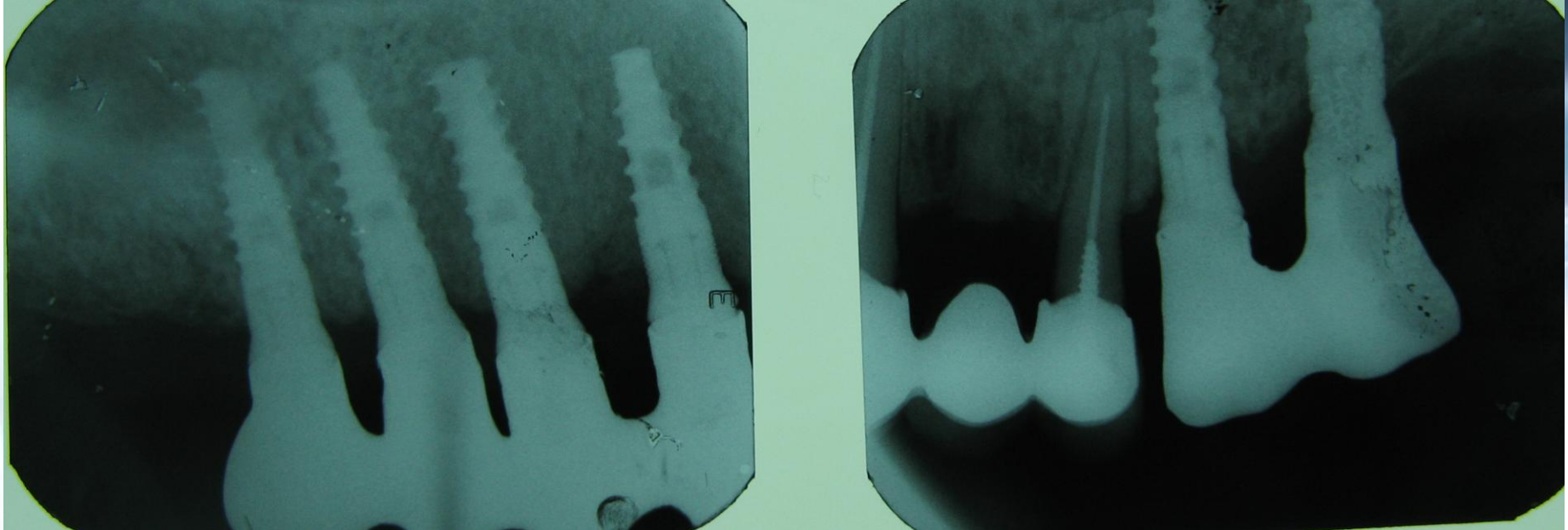
Cortex Premium package abutments



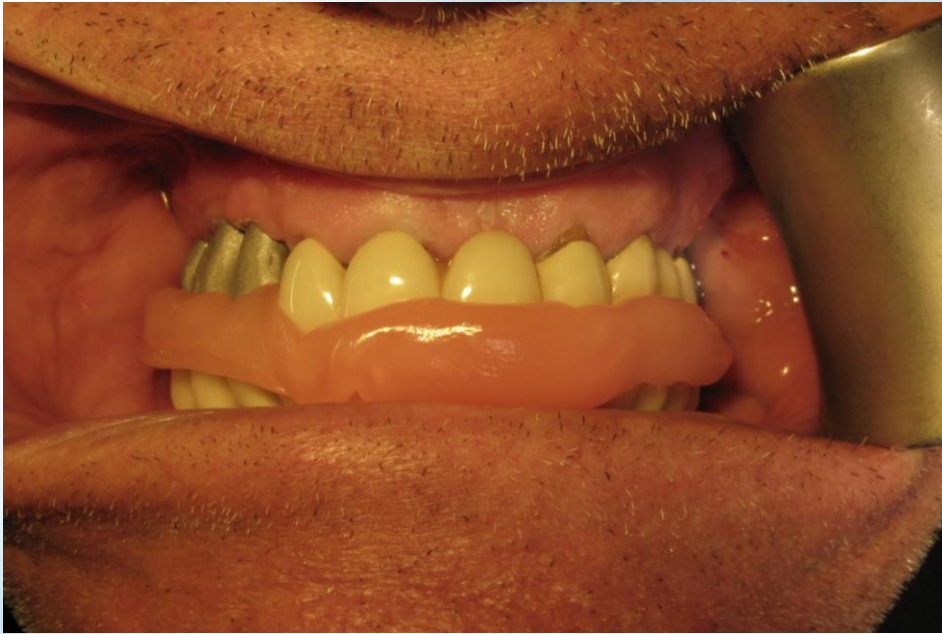

Metal crowns on
abutments



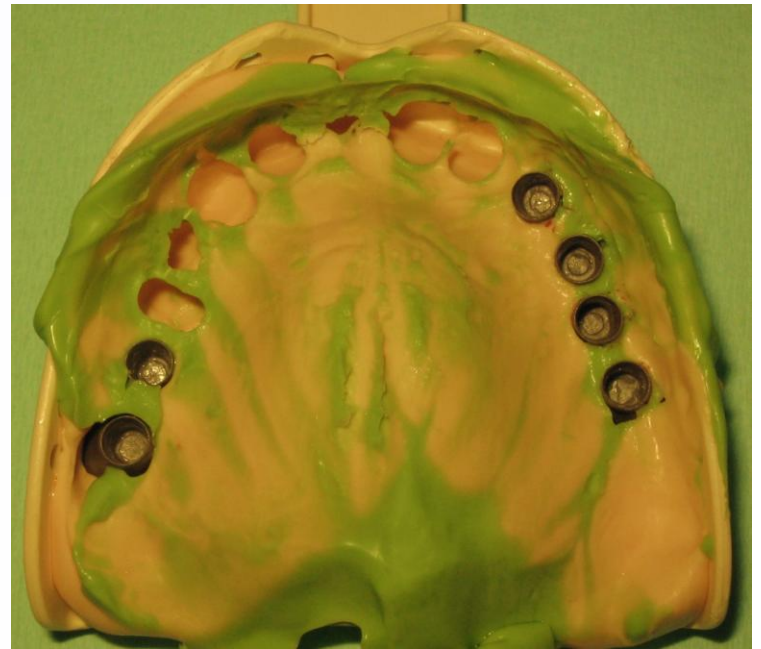

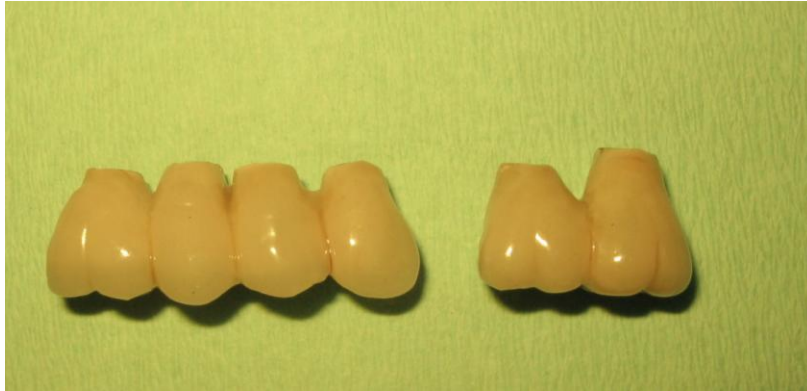X-ray of the metal crowns



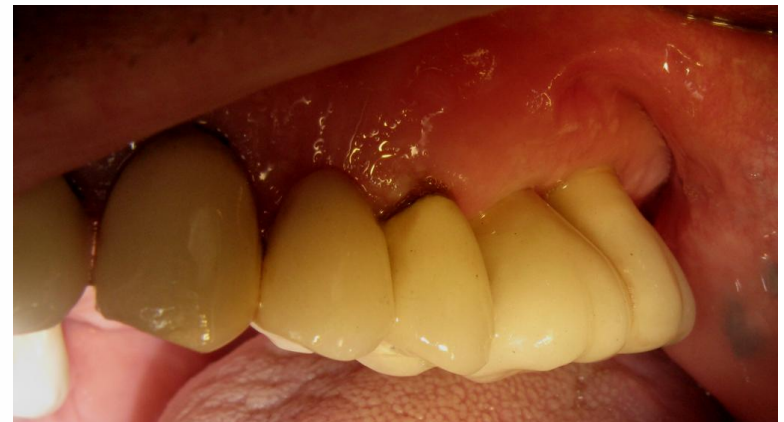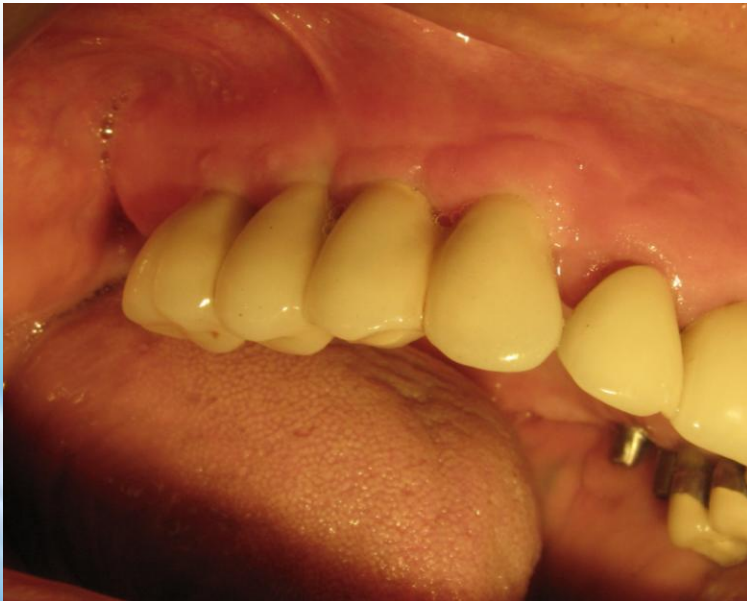Wax bite impression

Pick up impression





The final PFM crowns



CORTEX
dental implants

Smart.

